

Combination of modified techniques for percutaneous closure of a large secundum atrial septal defect

Judyta Szeliga¹, Paweł Dryżek², Andrzej Rudziński¹, Sebastian Góreczny¹

¹Department of Paediatric Cardiology, University Children's Hospital, Faculty of Medicine, Jagiellonian University Medical College, Krakow, Poland

²Department of Cardiology, Polish Mother's Memorial Hospital, Research Institute, Lodz, Poland

Adv Interv Cardiol 2023; 19, 2 (72): 178–181
DOI: <https://doi.org/10.5114/aic.2023.129217>

Large secundum atrial septal defects (ASD) with deficient or absent rim(s) remain a challenge for percutaneous closure and may require modified implantation techniques for successful device delivery [1]. Deployment from the right upper pulmonary vein or balloon-assisted positioning are effective methods of device implantation in challenging defects [2, 3]. However, in some patients even these techniques fail, and repeat attempts of device positioning or significant device oversizing may lead to complications [4]. We present a combination of modified implantation techniques for closure of a large secundum atrial septal defect with deficient rims.

During a routine examination of an asymptomatic, 13-year-old girl regularly practicing sports (59 kg) a murmur over the heart was heard. Transthoracic echocardiography showed a large secundum atrial septal defect with deficient aortic rim, right ventricular dilation, and moderate tricuspid regurgitation with a pressure gradient of 45 mm Hg.

Tranoesophageal echocardiography (Figure 1), performed under general anaesthesia, confirmed a large secundum atrial septal defect measuring up to 27 mm with deficient aortic rim, floppy inferior vena cava rim, and a short superior vena cava rim.

Subsequently, right and left heart catheterization was performed. In view of favourable haemodynamic measurements – the mean pulmonary artery pressure of 15 mm Hg, indexed pulmonary vascular resistance of 1.0 Wood Units, and pulmonary-to-systemic flow ratio of 3.2 : 1 – the decision was made to attempt defect closure.

A 30-mm Amplatzer Septal Occluder (Abbott) mounted on a classic delivery cable was introduced via a standard 10 Fr TorqueVue sheath (Abbott); however, due to the large size of the defect and deficient rims, a stable im-

plant position was not obtained. The left atrial disc slipped across the defect to the right atrium. Through an additional femoral vascular access, a 25-mm diagnostic sizing balloon catheter (NuMed) was inserted into the defect. Next, the balloon was simultaneously inflated (Figure 2 A) and the left atrial disc was deployed starting in the right upper pulmonary vein (Figures 2 B, C) followed by deployment of the right atrial disc (Figures 2 C, D). With stable device position the balloon was deflated (Figures 2 E) and gently withdrawn. After echocardiographic confirmation of the optimal position of the occluder and unobstructed flow from the superior vena cava, the device was released (Figure 2 F). With a combination of 2 modified techniques the device was deployed successfully in the first attempt.

Transthoracic echocardiography performed on the following day showed stable implant position without colliding with intracardiac structures. Further hospital stay and follow-up were uneventful. The device remained stable in 6 months of follow-up without residual flow. The tricuspid insufficiency diminished to mild just 1 month after implantation, with simultaneous gradient reduction to 17 mm Hg.

Percutaneous device closure of secundum atrial septal defects is routine clinical practice [5]. Occasionally, large size of the defect, deficient rim(s), or floppy septum warrant modified implantation techniques, which also come with some disadvantages [2, 3]. For instance, the balloon-assisted technique requires additional vascular access, and disc deployment in the pulmonary vein creates a risk of vein perforation. Furthermore, multiple attempts of device deployment may increase the likelihood of damaging the pulmonary vein or atrial wall [4].

A recently introduced novel delivery system, providing major flexibility and tension reduction, enables more

Corresponding author:

Prof. Sebastian Góreczny MD, PhD, Department of Paediatric Cardiology, University Children's Hospital, Faculty of Medicine, Jagiellonian University Medical College, Krakow, Poland, e-mail: sebastian.goreczny@uj.edu.pl

Received: 1.03.2023, accepted: 13.03.2023.

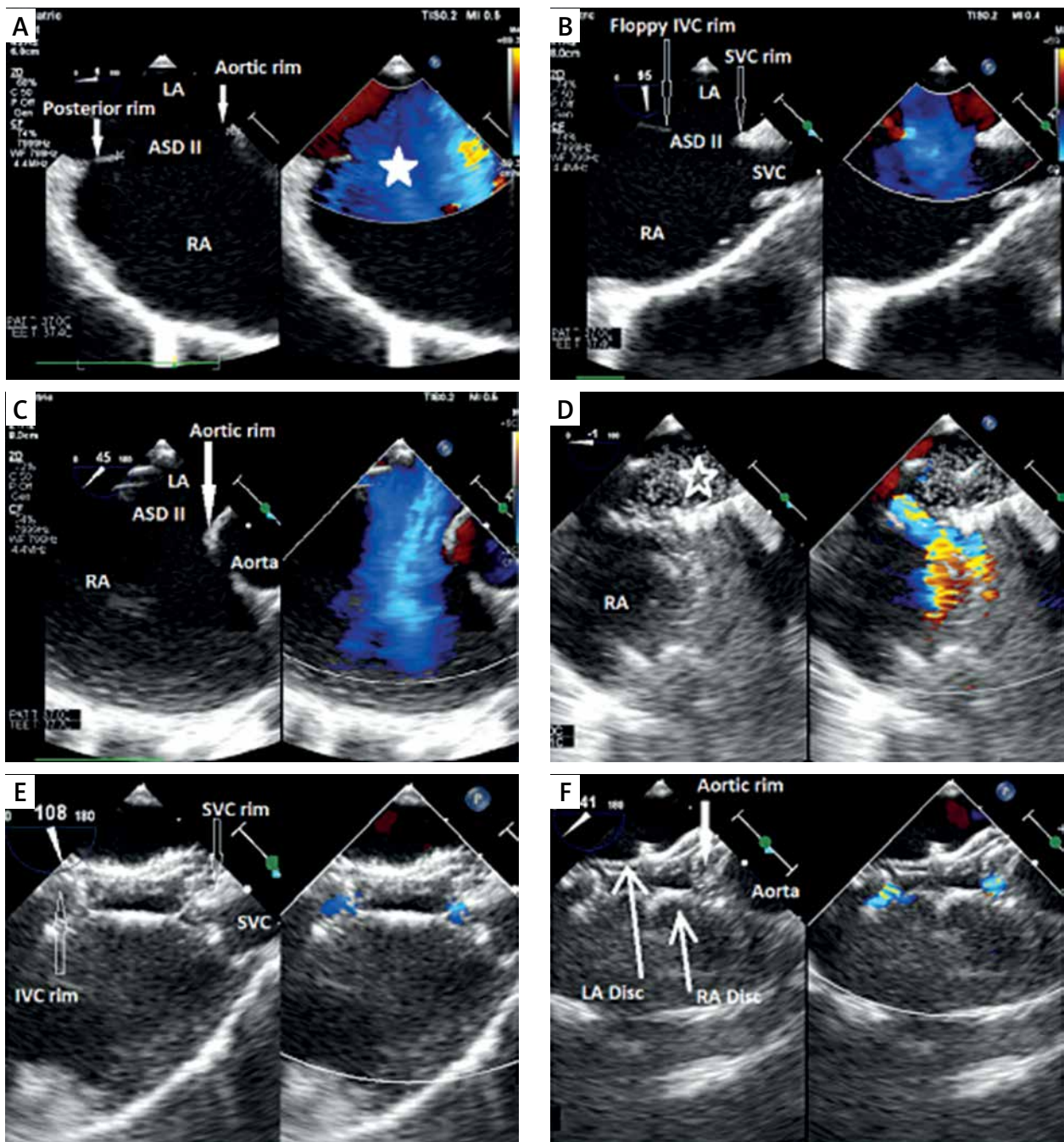


Figure 1. Transoesophageal images of device closure of a large secundum atrial septal defect with deficient superior vena cava. **A** – Four-chamber view (zoom); on the left side: secundum atrial septal defect in the middle part of the septum, dilated right atrium. Good visualization of the present posterior rim and deficient aortic rim; on the right side: TEE with colour Doppler showing a very large atrial septal defect with left-to-right shunt (white star). **B** – Bicaval view presenting a short superior vena cava rim and thin and floppy inferior vena cava rim. **C** – Short-axis view focused on the aortic valve showing lack of the aortic rim. **D** – Sizing balloon catheter inflated across the defect (empty white star) during simultaneous device deployment from the right upper pulmonary vein. **E** – Final result after release of the device; bicaval view with colour Doppler compare TEE showing typical device conformation with small residual leaks and unobstructed flow from the superior vena cava. **F** – Final result after release of the device: short-axis view with colour Doppler compare presenting the occluder well positioned on the aorta with small residual flow

SVC – superior vena cava, IVC – inferior vena cava, Ao – aortic valve, LA – left atrium, RA – right atrium, ASD II – secundum atrial septal defect.

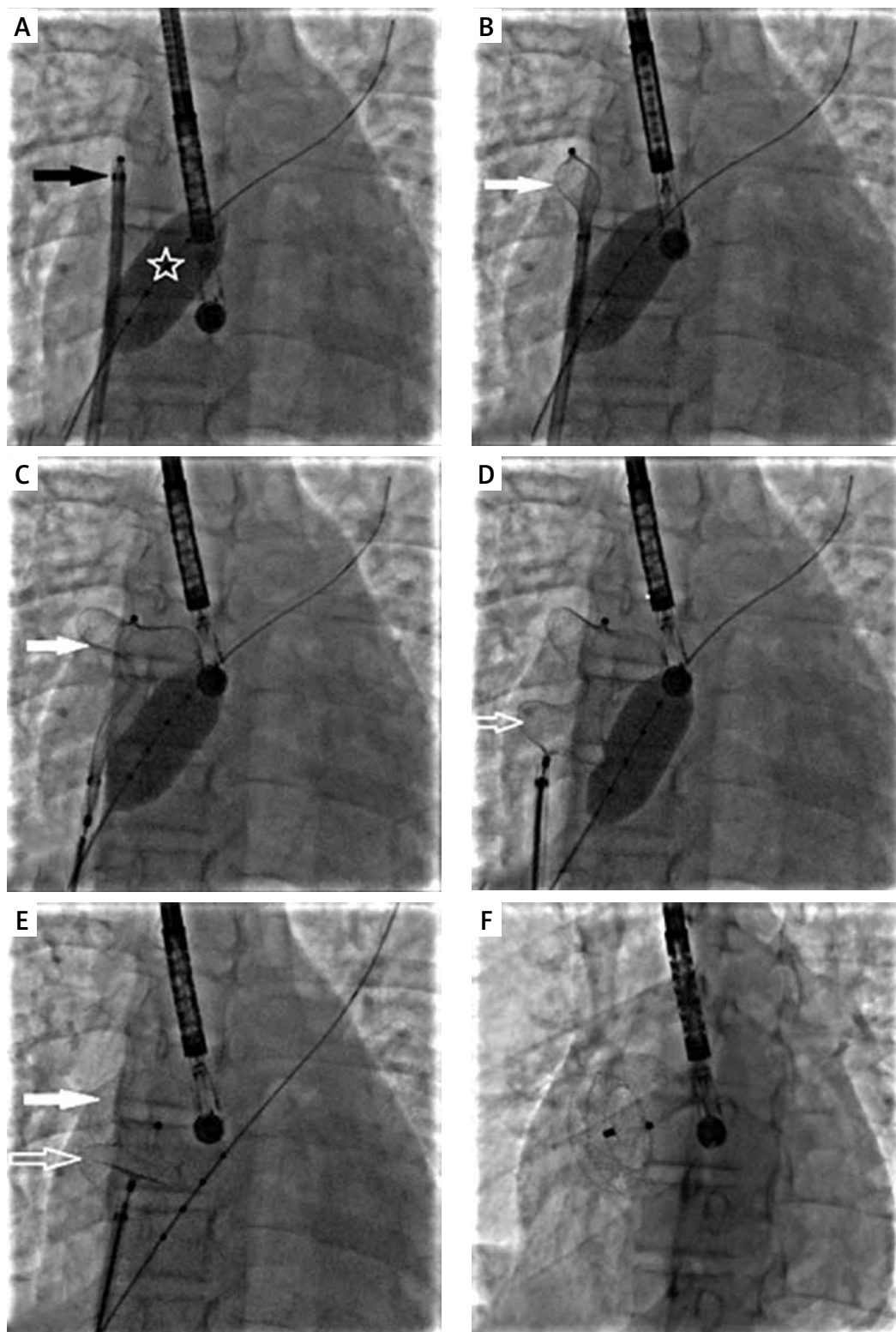


Figure 2. Percutaneous large secundum atrial septal defect closure with combination of modified techniques. **A** – A sizing balloon (white star) is inflated with the long sheath and the occluder (black star) ready for deployment in the right upper pulmonary vein. **B** – The left atrial disc (white arrow) being deployed in the right upper pulmonary vein. **C** – The left atrial disc (white arrow) fully deployed with the sizing balloon inflated. **D** – The right atrial disc (white empty arrow) deployed with sizing balloon inflated. **E** – Gradual deflation of the sizing balloon after both discs have been deployed and progressive conformation of the discs (white arrows) as the balloon is completely deflated. **F** – Final position of the device after release

predictable and efficient device closure of large atrial septal defects [6]. In cases when conventional technique and improved delivery system prove insufficient, a combination of modified techniques, such as balloon assistance and right upper pulmonary vein approach, enable successful device delivery even in a single attempt and exclude the need for significant device upsizing.

Acknowledgments

Thanks to Anna Grondalski from the Medical University of Szczecin for editing the text.

Conflict of interest

The authors declare no conflict of interest.

References

1. Kannan BR, Francis E, Sivakumar K, et al. Transcatheter closure of very large (≥ 25 mm) atrial septal defects using the Amplatzer septal occluder. *Catheter Cardiovasc Interv* 2003; 59: 522-7.
2. Narin N, Baykan A, Argun M, et al. New modified balloon-assisted technique to provide appropriate deployment in the closure of large secundum atrial septal defect using amplatzer septal occluder in children. *J Invasive Cardiol* 2014; 26: 597-602.
3. Góreczny S, Morgan GJ, Bilska K, et al. Balloon-assisted closure of a large atrial septal defect – guaranteeing a soft landing. *Kardiologia Pol* 2015; 73: 459.
4. Amin Z, Hijazi ZM, Bass JL, et al. Erosion of Amplatzer septal occluder device after closure of secundum atrial septal defects: review of registry of complications and recommendations to minimize future risk. *Catheter Cardiovasc Interv* 2004; 63: 496-502.
5. Grygier M, Sabiniewicz R, Smolka G, et al. Percutaneous closure of atrial septal defect: a consensus document of the joint group of experts from the Association of Cardiovascular Interventions and the Grown-Up Congenital Heart Disease Section of the Polish Cardiac Society. *Kardiologia Pol* 2020; 78: 1066-83.
6. Haddad RN, Khraiche D, Bonnet D, et al. Preliminary experience with the new Amplatzer™ Trevisio™ delivery system in transcatheter atrial septal defect closures in children. *Front Pediatr* 2021; 9: 641-742.