

Entrapment of the median nerve and the brachial artery by the *lacertus fibrosus*

Hitendra Kumar¹, Srijit Das², Sonali Gaur³

¹Department of Anatomy, Vardhaman Mahavir Medical College and Safdarjung Hospital, New Delhi, 1100029, India

²Department of Anatomy, Universiti Kebangsaan Malaysia, 50300 Kuala Lumpur, Malaysia

³TAPS Hospital, Boisar, Thane, Mumbai, India

Submitted: 23 May 2007

Accepted: 3 August 2007

Arch Med Sci 2007; 3, 3: 284-286

Copyright © 2007 Termedia & Banach

Corresponding author:

Dr. Hitendra Kumar, MBBS, MS
J-974

Ansals Palam Vihar
Gurgaon-122017, Haryana
India

Phone: +91 935 080 94 34;
+91 124 407 49 74

E-mail: drhitendra3@yahoo.com

Abstract

The *lacertus fibrosus* is a lesser known cause of high median nerve compression along with the brachial artery. Considering the fact that anatomy literature hardly mentions the *lacertus fibrosus*, research reports are the only source of information for clinicians and surgeons. The present case report describes in detail the *lacertus fibrosus* pierced by the median nerve and the brachial artery and discusses its clinical implications, which may be important for clinicians diagnosing nerve entrapment and surgeons operating on the arm.

Key words: *lacertus fibrosus*, entrapment, median nerve.

Introduction

The biceps is a large fusiform muscle, which has a long and short head. The long head originates from the supraglenoid tubercle and the adjacent portion of the glenoid labrum of the scapula, while the short head originates from the apex of the coracoid process [1, 2]. Both the heads join together to form the belly of the biceps. At the lower end the belly forms a tendon that inserts into the radial tuberosity of radius [1, 2]. Other than the terminal portion of the tendon of the biceps, there is an extension which is in fact an aponeurotic expansion, fusing with the antebrachial fascia, and this is termed the "*lacertus fibrosus*" [1].

The most frequently occurring variation of the biceps brachii is the presence of a third head, and this has been reported to occur in 8% of Chinese, 10% of Europeans, 12% of Africans and 18% of Japanese [3]. The majority of the studies have focused on abnormalities of the third head; one of these has defined the third head to originate from the distal portion of the pectoralis major muscle [4]. In a search of the extant literature, we found that there is a paucity of reports about the incidence and clinical implications of *lacertus fibrosus*. The concomitant entrapment of the median nerve and the brachial artery in a single individual as seen in the present case may be a startling finding to acknowledge.

The main purpose of the present study is to report a case of simultaneous entrapment of the median nerve and brachial artery by a thick *lacertus fibrosus* and discuss its clinical implications. Knowledge of the *lacertus fibrosus* may assist clinicians and surgeons to diagnose and operate upon median nerve entrapment of the lower arm.

Case report

During routine dissection of a cadaver, we noted the entrapment of both the median nerve and the brachial artery by the *lacertus fibrosus* in the right arm of a 47-year-old male, who died of a road traffic accident. The superficial and the deep structures were carefully dissected from the shoulder to the upper forearm. The specimen was studied and photographed (Figure 1).

In the right upper limb, a very thick fibro-aponeurotic band, the *lacertus fibrosus*, was observed at the lower end of the biceps brachii muscle. This was in fact continuous with the medial border of the muscle. It proceeded medially and downwards towards the medial epicondyle of the humerus to become the ante brachial fascia of the forearm. The median nerve and the brachial artery pierced through the *lacertus fibrosus* (Figure 1). The median nerve and the brachial artery were in their usual position. The median nerve and the brachial artery were found to pierce the thick sheet of the *lacertus fibrosus* while descending into the elbow (Figure 1). It was as if the *lacertus fibrosus* tethered to the median nerve and the brachial artery. No other abnormalities were observed.

Discussion

The *lacertus fibrosus* is in fact an aponeurotic expansion of the biceps which fuses with the antebrachial fascia [1]. We do agree that LF may be

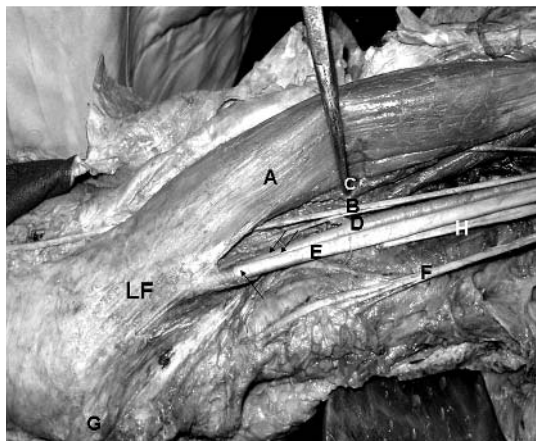


Figure 1. Photograph of the dissected right upper limb showing: **A** – biceps brachii muscle (lifted and turned laterally), **B** – musculocutaneous nerve, **C** – biceps brachii after being lifted laterally by forceps, **D** – brachial artery, **E** – median nerve, **F** – medial cutaneous nerve of arm, **G** – medial epicondyle, **H** – ulnar nerve, **LF** – *lacertus fibrosus*
Note: The median nerve lying superficially is shown with single arrow while the brachial artery lying deep to it is shown with double arrows. The median nerve and the brachial artery can be clearly seen to pierce the *lacertus fibrosus*

a common finding but it was extremely thick in this case and was concurrently entrapping the median nerve and the brachial artery. There are reports of compression of the musculocutaneous nerve and the brachial artery by the *lacertus fibrosus* [5-7] but in the present case we observed the median nerve and the brachial artery being compressed in the same individual.

There are previous research reports of the median nerve being entrapped by the Struther's ligament, in pronator syndrome, and also involved in supracondylar fractures of the humerus [8-10]. In the present case, none of the above causes were observed. The entrapment of both the median nerve and the brachial artery in the same individual, as seen in this case, may have great clinical significance. It has been reported in earlier studies that there might be compression of the brachial artery, which may result in claudication type of pain with cold intolerance and loss of radial and ulnar pulses with pronation [5, 7]. During their course the median nerve and the brachial artery, passing beneath the *lacertus fibrosus*, may get compressed and produce symptoms like paresthesia, numbness, weakness and fatigue with insidious onset and without any precipitating cause [11]. There are many reports on compression of the median nerve at the elbow by the *lacertus fibrosus* with or without trauma [12-14]. Admittedly, we did not have any history to corroborate the clinical symptoms in this patient.

Anatomical variations in the lower arm may be important for clinicians and surgeons. Clinicians may be aware of the *lacertus fibrosus* compressing the median nerve. The correlation of the onset of symptoms with sudden severe flexion injury against resistance may raise doubts of median nerve involvement [11]. Electro-diagnostic tests may be carried out to arrive at a conclusion. Electro-diagnostic tests with parameters such as threshold, slope and plateau of input-output curves may show changes in motor axon recruitment of the median nerve [15]. Many cases may be treated with conservative methods, but cases of persistence of symptoms beyond 3 months may require surgical intervention in which the *lacertus fibrosus* may have to be released [11].

Conclusions

We as anatomists thus opine that presence of a thick *lacertus fibrosus* may result in compressive symptoms involving the median nerve and brachial artery. Awareness of such anomalies may be important for clinicians diagnosing high median nerve entrapment and surgeons operating on the arm.

References

1. Rodríguez-Vázquez JF, Mérida-Velasco JR, Jiménez-Collado J. Unusual variation of a third head of the biceps brachii muscle. *Ann Anat* 1999; 181: 573-5.
2. Sinnatamby CS (ed). *Last's Anatomy: Regional and Applied*. 10th ed. Churchill Livingstone, Edinburgh, 1999.
3. Bergman RA, Thompson SA, Afifi AK. *Catalog of Human Variation*. Urban and Schwarzenberg, Baltimore and Munich, 1984.
4. Sargon MF, Tuncali D, Celik HH. An unusual origin for the accessory head of biceps brachii muscle. *Clin Anat* 1996; 9: 160-2.
5. Bassett FH 3rd, Nunley JA. Compression of the musculocutaneous nerve at the elbow. *J Bone Joint Surg Am* 1982; 64: 1050-2.
6. Bassett FH 3rd, Spinner RJ, Schroeter TA. Brachial artery compression by the lacertus fibrosus. *Clin Orthop Relat Res* 1994; 307: 110-6.
7. Biemans RG. Brachial artery entrapment syndrome. Intermittent arterial compression as a result of muscular hypertrophy. *J Cardiovasc Surg* 1977; 18: 367-71.
8. Smith RV, Fisher RG. Struthers ligament: a source of median nerve compression above the elbow. Case report. *J Neurosurg* 1973; 38: 778-9.
9. Spinner M, Spencer PS. Nerve compression lesions of the upper extremity. A clinical and experimental review. *Clin Orthop Relat Res* 1974; 104: 46-67.
10. Laha RK, Dujovny M, DeCastro SC. Entrapment of median nerve by supracondylar process of the humerus. Case report. *J Neurosurg* 1977; 46: 252-5.
11. Seitz WH, Matsuoka H, McAdoo J, Sherman G, Stickney D. Acute compression of the median nerve at the elbow by the lacertus fibrosus. *J Shoulder Elbow Surg* 2007; 16: 91-4.
12. Bilge T, Yalaman O, Bilge S, Cokneseli B, Barut S. Entrapment neuropathy of the median nerve at the level of the ligament of Struthers. *Neurosurgery* 1990; 27: 787-9.
13. Foxworthy M, Kinninmonth AW. Median nerve compression in the proximal forearm as a complication of partial rupture of the distal biceps brachii tendon. *J Hand Surg [Br]* 1992; 17: 515-7.
14. Gessini L, Jandolo B, Pietrangeli A. Entrapment neuropathies of the median nerve at and above the elbow. *Surg Neurol* 1983; 19: 112-6.
15. Ginanneschi F, Mondelli M, Dominici F, Rossi A. Changes in motor axon recruitment in the median nerve in mild carpal tunnel syndrome. *Clin Neurophysiol* 2006; 117: 2467-72.