

# Effective combination of lamivudine with ursodeoxycholic acid in the treatment of acute flare of chronic hepatitis B infection after discontinuation of lamivudine therapy

Krisztina Hagymási<sup>1</sup>, Gabriella Lengyel<sup>1</sup>, Margit Horányi<sup>2</sup>, Gábor Mester<sup>3</sup>, János Fehér<sup>1</sup>

<sup>1</sup>2<sup>nd</sup> Department of Internal Medicine, Medical Faculty, Semmelweis University, Budapest, Hungary

<sup>2</sup>OGYK, Virological Laboratory, Budapest, Hungary

<sup>3</sup>Cholnoky F. Hospital, Veszprém, Hungary

**Submitted:** 26 July 2005

**Accepted:** 14 August 2005

Arch Med Sci 2005; 1, 2: 119-122

**Corresponding author:**

Krisztina Hagymási, MD, PhD

2<sup>nd</sup> Dept. of Internal Medicine

Medical Faculty

Semmelweis University

H-1088 Budapest

Szentkirályi u. 46, Hungary

Phone/fax: 0036 1 317 45 48

E-mail: hagymasikriszti@freemail.hu

## Abstract

Lamivudine is an effective nucleoside-analogue for the treatment of chronic hepatitis B. However, treatment withdrawal after 1 year has been associated with a high rate of relapse, while long-term treatment is associated with an increasing risk of drug resistance. The authors summarise the case of a 66-year old male with HBeAg-negative hepatitis B cirrhosis. With a 14-month lamivudine treatment (100 mg/day orally) only partial (biochemical) response was achieved. Serum HBV DNA sustained positive but the lamivudine treatment was stopped because it was not budgeted for. After 18 months of discontinuation of the lamivudine therapy – without any connection with the cessation of the nucleoside-analogue therapy – serious icteric flare of HBV cirrhosis occurred. Reinstitution of lamivudine completed with ursodeoxycholic acid resulted in virological and biochemical responses. In the future, a combination therapy for chronic HBV infection can be anticipated.

**Key words:** lamivudine, ursodeoxycholic acid, combined treatment, HBeAg-negative chronic hepatitis B.

## Introduction

Lamivudine was the first nucleoside-analogue licensed for the treatment of chronic viral hepatitis B. It is safe and effective in patients with decompensated liver disease, improves liver function and survival in many patients [1]. However, treatment withdrawal after 1 year has been associated with a high rate of relapse, while long-term treatment is associated with an increasing risk of drug resistance. Lamivudine induces initial complete (biochemical, virological) response in 70-90% of patients. After discontinuation of the therapy, viraemia relapses and only 30-40% of patients remain in remission after the third year. Hepatitis B virus (HBV) reactivation can lead to liver decompensation and death [2-4].

Endogenous (host immune tolerance) and exogenous factors (vaccines and antiviral drugs, e.g. nucleotide analogues, hepatitis B immunoglobulins) are responsible for the selection of hepatitis B virus mutants. The frequency of HBV mutation has been estimated to be around  $1.4-3.2 \times 10^{-5}$  nucleotide substitutions/site/year. This is approximately 10-fold higher than that of other DNA viruses, and may be a consequence of the lack of proof-reading capability.

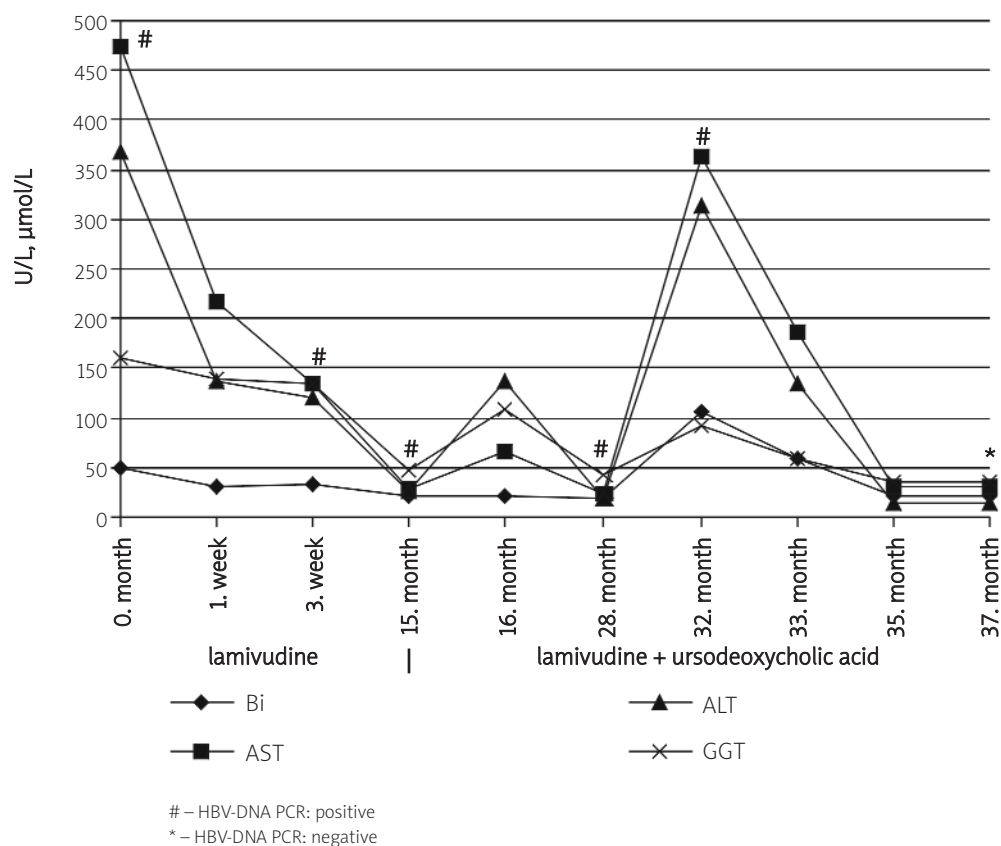


Figure 1. Laboratory parameters of the patient during the therapy

Viral mutations play a role in the clinical outcome of infection, progression and antiviral drug resistance [5].

### Case report

A 66-year old plumber was admitted in March 2001 to the Department of Internal Medicine of County Hospital Cholnoky Ferenc for elevated liver enzyme activities, compact hepatomegaly, esophageal varices (grade II) and reflux esophagitis (st. II) diagnosed by ambulatory examinations in the background of epigastric pain, abdominal distension, fatigue, sleepiness. He had no history of transfusion or icterus. Multiple minor and major surgeries were in his anamnesis because of recidive otitis media, nephrolithiasis and renal tuberculosis.

On the admission to the medical department abdominal examination revealed meteorism and hepatomegaly. The serum bilirubin level was 49 μmol/L, aspartate aminotransferase (AST) was 474 U/L, alanine aminotransferase (ALT) was 369 U/L, alkaline phosphatase (ALP) was 311 U/L, gamma-glutamyl-transpeptidase (GGT) was 161 U/L and mean corpuscular volume (MCV) was 106 fL (abnormal liver function tests had existed for more than one year).

The renal function was normal. The ultrasound scan showed hepatomegaly, diffusely increased inhomogeneous echotexture, rough-granular structure without focal lesions, biliary tree alterations, vascular abnormalities, gallstone, and normal spleen size. The left kidney was resected. His hepatitis B surface antigen (HBsAg), IgM anti hepatitis B core antigen (anti-HBc IgM), antibodies to HBe antigen (anti-HBe) was positive, and the hepatitis e antigen (HBeAg) was negative. HBV DNA PCR (cutoff >100-200 copia/mL) was positive. Anti-HCV was negative. Biopsy was not performed because of the unambiguous clinical picture and the patient's compliance.

The clinical picture with the knowledge of laboratory and ultrasonography findings showed clearly the vascular and parenchymal decompensation of HBV cirrhosis hepatis. At the end of the one-week hospitalization clinical and laboratory (bilirubin: 31,4 μmol/L, AST: 216 U/L, ALT: 137 U/L, GGT: 139 U/L, ALP: 257 U/L) improvement was achieved with supportive treatment (folic acid, vitamin B1, B6, K, furosemide, omeprazole, silymarin). At the end of April 2001 lamivudine treatment (Zeffix, GlaxoSmithKline, 100 mg/day orally) was started at the Hepatological Outpatient Department of II. Dept. of Internal

Medicine, Medical Faculty, Semmelweis University, besides the omeprazole and silymarin treatment. His laboratory parameters and clinical symptoms improved further. In July 2002 the lamivudine treatment was stopped because of it was not budgeted for. Only biochemical, incomplete response could be achieved: the liver enzyme activities were in normal range, but HBV DNA positivity existed. Abdominal ultrasonography showed hepatomegaly with inhomogen, grainy structure and splenomegaly. During one and a half year follow up he had no complaints at all.

In January 2004 he was observed again because of icterus and pruritus. The laboratory parameters confirmed the suspicion of acute exacerbation. The bilirubin was 107  $\mu\text{mol/L}$ , AST was: 364 U/L, ALT was: 313 U/L, GGT was: 91 U/L, ALP was: 248 U/L. The ultrasonography showed hepatomegaly, small ascites, and nephrolithiasis l.s. The exact cause of the icteric flare remained unknown. Hepatitis C, D virus coinfections were excluded, as well as alcohol consumption. The combined antiviral (lamivudin, 100 mg/day) and ursodeoxycholic acid (Ursofalk, Dr. Falk Pharma, 3 x 250 mg/day) treatment was started. Reinstitution of lamivudine completed with ursodeoxycholic acid resulted in virological and biochemical responses. The level of bilirubin and liver enzyme activities gradually decreased (Figure 1.), the clinical symptoms improved as well, in August 2004 liver enzyme activities were in the normal range, and the patient became HBV DNA negative.

## Discussion

This case illustrates a serious presentation of icteric flare of chronic hepatitis B after discontinuation of nucleoside-analogue therapy – without any connection with the cessation of the therapy.

HBeAg-negative chronic hepatitis B represents a late phase in the natural course of chronic HBV infection that develops after HBeAg loss and seroconversion to anti-HBe. It is usually associated with pre-core stop codon mutation at nucleotide 1896 (mainly selected in non-A HBV genotypes), but also with other pre-core changes or with mutations in the basic core promoter region (mainly in HBV genotype A) [5]. HBeAg-negative chronic hepatitis B is more common than previously suspected with median prevalence of 33% in the Mediterranean region and 14% in the USA and Northern Europe [6]. The diagnosis of HBeAg-negative chronic hepatitis B infection is based on HBsAg positivity, HBeAg negativity, and mainly on increased alanine aminotransferase (ALT) and serum HBV-DNA levels and exclusion of other causes of liver disease [7]. The HBeAg-negative mutants prevail over the wild type HBV, and can escape from the IFN-boosted immuno-elimination [8]. Patients with

HBeAg-negative chronic hepatitis tend to be older, male and to present with severe necroinflammation. The persistence of viraemia and serum aminotransferases elevations in HBeAg-negative chronic hepatitis B patients is frequently accompanied by progressive liver disease and poorer prognosis. 60% of patients with this form of disease develop cirrhosis within 6 years (8-10%/year vs 2-5.5% in HBeAg-positive chronic hepatitis B) [6, 9].

Lamivudine is a nucleoside analogue with a potent inhibitory effect on hepatitis B virus polymerase/reverse transcriptase activity. In hepatitis B e antigen negative/hepatitis B virus DNA-positive (precore mutant) chronic hepatitis B lamivudin treatment (100 mg/day) induces initial complete response (loss of serum HBV DNA plus normalization of alanine transaminase) in 70-90% of patients, which is similar to the response reported in previous studies of patients with HBeAg-positive chronic hepatitis B [7, 10, 11]. Breakthroughs due to lamivudine-resistant mutants accumulate with continuation of therapy, and thus after discontinuation of lamivudine therapy disease and viraemia relapse and only 30-40% of patients remain in remission after the third year due to progressively increasing viral resistance [7, 11-14]. Drug resistance occurs in 20% of patients after 12 months and increases with duration of the therapy (55% at 3 years) [15]. YMDD (tyrosine-methionine-aspartate-aspartate amino acid motif of HBV polymerase) mutants explained the 75% of lamivudine resistance [16]. To date, there is no proven effective therapy for the resistant HBV mutant strains, although adefovir and entecavir seem to be interesting candidates [11].

Ursodeoxycholic acid is used for gallstone dissolution and currently the only established drug for the treatment of chronic cholestatic liver diseases. It has cytoprotective, anti-apoptotic, membrane stabilizing, anti-oxidative, immunomodulatory and signal transduction pathways affecting effects. It also has a beneficial effect on various liver diseases (primary sclerosing cholangitis, intrahepatic cholestasis of pregnancy, liver disease associated with cystic fibrosis, chronic graft versus host disease, total parenteral nutrition associated cholestasis and various pediatric cholestatic liver diseases) [17-19]. Bile acid treatment leads to a significant improvement of cholestatic indices in acute viral hepatitis [20], enhances the clearance of the hepatitis B virus and thus prevents the development of chronic hepatitis as well [21]. In one trial, ursodeoxycholic acid (UDCA) versus placebo for acute hepatitis B significantly reduced the risk of hepatitis B surface antigen positivity at the end of treatment and serum HBV DNA level at the end of follow-up. In another trial, UDCA versus no intervention for chronic hepatitis B significantly reduced the risk of having abnormal serum transaminase activities at the end of treatment [22].

In our case the combined lamivudine and ursodeoxycholic acid treatment resulted in complete response (normalization of biochemical markers, loss of HBV DNA) of patients with acute flare of chronic hepatitis B after 1.5 year of discontinuation of lamivudine monotherapy.

In the future, the combination therapy for chronic HBV infection can be anticipated. Immunomodulation can be combined with viral suppression to achieve more efficacy and safety with reduced side-effects. Utilization of two or more anti-HBV drugs would be predicted to enhance efficacy and reduce the likelihood of emergence of drug resistance [15]. Combination of interferon alfa with lamivudine showed little additional benefit in an initial trial of Scham et al. Combination of two (or more) nucleoside analogue keeps viral suppression to a maximum, but reducing the chance that resistance will develop [1]. Telbuvudine-lamivudine and adefovir-lamivudine therapy showed no additional benefit over telbuvudine/lamivudine monotherapy [1]. Early results show that lamivudine combined with traditional Chinese medicine have higher efficiency than lamivudine alone in the treatment of chronic hepatitis B [23].

## References

1. Lai CL, Ratziu V, Yuen M-F, Poynard, T. Viral hepatitis B. *Lancet* 2003; 362: 2089-94.
2. Barbon V, Gaia S, Marzano A, Lagget M, Rizzetto M. Prompt relapse of viremia after lamivudine discontinuation in e-minus chronic hepatitis B patients completely responders during 5 years of therapy. *J Hepatol* 2004; 41: 500-1.
3. Honkoop P, de Man RA, Niesters HG, Zondervan PE, Shalm SW. Acute exacerbation of chronic hepatitis B virus infection after withdrawal of lamivudine therapy. *Hepatology* 2000; 32: 635-9.
4. Lim SG, Wai CT, Rajnakova A, Kajiji T, Guan R. Fatal hepatitis B reactivation following discontinuation of nucleoside analogues for chronic hepatitis B. *Gut* 2002; 51: 597-9.
5. Locarnini S. Relevance of HBV mutations in severity and progression of chronic hepatitis B. *J Gastroenterol Hepatol* 2004; 19: S108-12.
6. Rizzetto M, Tassopoulos NC, Goldin RD, Esteban R, Santantonio T, Heathcote EJ, et al. Extended lamivudine treatment in patients with HBeAg-negative chronic hepatitis B. *J Hepatol* 2005; 42: 173-9.
7. Papatheodoridis GV, Hadziyannis SJ. Diagnosis and management of pre-core mutant chronic hepatitis B. *J Viral Hepat* 2001; 8: 311-21.
8. Chen WN, Oon CJ. Hepatitis B virus mutants: an overview. *J Gastroenterol Hepatol* 2002; 17: S497-9.
9. Lavanchy D. Hepatitis B virus epidemiology, disease burden, treatment, and current and emerging prevention and control measures. *J Viral Hepatitis* 2004; 11: 97-107.
10. Tassopoulos NC, Volpes R, Pastore G, Heathcote J, Buti M, Goldin RD, et al. Efficacy of lamivudine in patients with hepatitis B e antigen negative/hepatitis B virus DNA positive (pre-core mutant) chronic hepatitis B. Lamivudine precore mutant study group. *Hepatology* 1999; 29: 889-96.
11. Papatheodoridis GV, Hadziyannis SJ. Current management of chronic hepatitis B. *Aliment Pharmacol Ther* 2004; 19: 25-37.
12. Hadziyannis SJ, Papatheodoridis GV, Vassilopoulos D. Treatment of HBeAg-negative chronic hepatitis B. *Semin Liver Dis* 2003; 23: 81-8.
13. Di Marco V, Marzano A, Lampertico P, Andreone P, Santantonio T, Almasio PL, et al. Clinical outcome of HBeAg-negative chronic hepatitis B in relation to virological response to lamivudine. *Hepatology* 2004; 40: 883-91.
14. Santantonio T, Mazzola M, Iacovazzi T, Miglietta A, Guastadisegni A, Pastore G. Long-term follow-up of patients with anti-HBe/HBV DNA-positive chronic hepatitis B treated for 12 months with lamivudine. *J Hepatol* 2000; 32: 300-6.
15. Straley SD, Terrault NA. Chronic hepatitis B. *Curr Treat Options Gastroenterol* 2004; 7: 477-89.
16. Gaia S, Marzano A, Smedile A, Barbon V, Abate ML, Olivero A, et al. Four years of treatment with lamivudine: clinical and virological evaluations in HBe antigen-negative chronic hepatitis B. *Aliment Pharmacol Ther* 2004; 20: 281-7.
17. Kumar D, Tandon RK. Use of ursodeoxycholic acid in liver diseases. *J Gastroenterol Hepatol* 2001; 16: 3-14.
18. Rodrigues CM, Steer CJ. The therapeutic effects of ursodeoxycholic acid as an anti-apoptotic agent. *Expert Opin Investig Drugs* 2001; 10: 1243-53.
19. Paumgartner G, Beuers U. Mechanisms of action and therapeutic efficacy of ursodeoxycholic acid in cholestatic liver disease. *Clin Liver Dis* 2004; 8: 67-81.
20. Fabris P, Tositti G, Mazzella G, Zanetti AR, Nicolini R, Pellizzer G, et al. Effect of ursodeoxycholic acid administration in patients with acute viral hepatitis. *Aliment Pharmacol Ther* 1999; 13: 1187-93.
21. Galsky J, Banský G, Holubová T, Koning J. Effect of ursodeoxycholic acid in acute viral hepatitis. *J Clin Gastroenterol* 1999; 28: 249-53.
22. Chen W, Liu J, Gluud C. Bile acids for viral hepatitis. *Cochrane Database Syst Rev* 2003; 2: CD003181.
23. Chen T, Chen WH. Advances of combined treatment for chronic hepatitis B with lamivudine. *Zhong Xi Yi Jie He Xue Bao* 2003; 1: 146-50.