

# Extrapulmonary tuberculosis following allogeneic stem cell transplantation – a difficult and late diagnosis

Agnieszka Tomaszewska, Barbara Nasiłowska-Adamska, Monika Prochorec-Sobieszek, Kazimierz Hałaburda, Andrzej Szczepiński, Bożena Mariańska

Institute of Hematology and Transfusion Medicine, Department of Haematopoietic Stem Cells Transplantation, Warsaw, Poland

**Submitted:** 27 July 2008

**Accepted:** 30 November 2008

Arch Med Sci 2009; 5, 3: 489-491  
Copyright © 2009 Termedia & Banach

## Abstract

Tuberculosis, especially with the extrapulmonary manifestation, is usually not considered as the first line in the differential diagnosis in patients after stem cell transplantation. We report a case of a 54-year old man after reduced intensity conditioning regimen allogeneic stem cell transplantation, without known personal or family history of tuberculosis, who presented knee joint, skin and bone marrow involvement by a *Mycobacterium tuberculosis* infection. A delay from the onset of the first symptoms to the confirmed diagnosis of tuberculosis was about 2 months in this case. Despite this delay, our patient successfully recovered after 4-tuberculostatics followed by 2-tuberculostatics therapy.

**Key words:** extrapulmonary tuberculosis, acute leukemia, transplantation.

## Corresponding author:

Agnieszka Tomaszewska, MD  
Institute of Haematology  
and Transfusion Medicine  
Department of Haematopoietic  
Stem Cells Transplantation  
14 Gandhi Str.  
02-776 Warsaw, Poland  
Phone: (48 22) 34 96 360  
Fax: (48 22) 34 96 361  
E-mail:  
agnieszka\_tomaszewska@onet.eu

## Introduction

Tuberculosis is an uncommon opportunistic infection after stem cell transplantation even in endemic areas [1, 2]. The main cause of this complication among stem cell transplant recipients is impaired cell-mediated immunity due their underlying disease, pre-transplant chemo/radiotherapy, graft versus host disease (GvHD) and its prophylaxis and treatment [2, 3]. It has been suggested that early occurrence of mycobacterial infections (MBIs) after stem cell transplantation is associated with poor prognosis and high mortality rate [3]. A major problem after transplantation is the lack of criteria to predict MBI [3]. Stem cells or solid organ transplantation (related to immunosuppressive therapy) is one of high risk factors for development of extrapulmonary MBI [3, 4]. Atypical clinical presentation of tuberculosis in this group of patient is the main challenge of health care providers [2, 3, 5].

In this case report we present a patient with atypical clinical picture of tuberculosis after stem cell transplantation and we overviewed the treatment outcome in this patient.

## Case report

A 54-year old male patient underwent allogeneic peripheral blood stem cell transplantation (PBSCT) from his Human Leukocyte Antigens (HLA)-identical brother, due to acute myeloid leukemia (AML) M2 according to FAB (French-American-British) classification in the first complete remission,

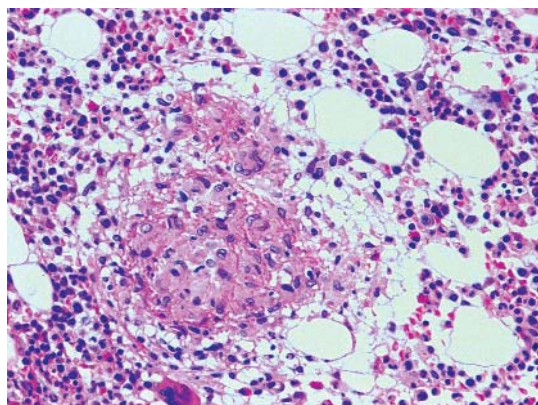
in September 2006. This patient, after a Reduced-Intensity Conditioning (RIC) regimen including busulphan (intravenous), 2-chlorodeoxyadenosine (2-CDA) and alemtuzumab (Campath), received  $5.71 \times 10^6/\text{kg}$  CD34+ cells and graft-versus-host disease (GvHD) prophylaxis was cyclosporine alone. No serious complications have been observed during the first phase after transplantation. Regeneration was as follows: WBC  $> 1.0 \times 10^9/\text{l}$  and ANC  $> 0.5 \times 10^9/\text{l}$  on the 18<sup>th</sup> post-transplantation day (PTD), PLT  $> 20 \times 10^9/\text{l}$  on the 11<sup>th</sup>, and  $> 50 \times 10^9/\text{l}$  on the 13<sup>th</sup> PTD. The patient didn't develop acute GvHD. He was given typical antibacterial, antiviral and antifungal medications as prophylaxis and cyclosporine A at the time of his discharge on the 21<sup>st</sup> PTD. After the patient's discharge, he followed up as an out-patient every week and later on every two weeks.

On the 61<sup>st</sup> PTD he was presented to our clinic with the skin lesions resembling furuncles on his forehead and arms which recovered after prescription of the systemic and local empiric antibiotics. One month later (the 89<sup>th</sup> PTD) he was presented with left knee joint edema and soreness without fever, weakness, lack of appetite and nausea. A knee and chest X-rays and a knee and abdomen ultrasonography were performed – without any abnormal findings. The improvement found on ketoprofen was very poor. On January 2007 he was readmitted to hospital because of anemisation to hemoglobin level 7.2 g/dl and weight loss (6 kg during one month). Compare to previous physical examination, his left knee edema was enlarged. Therefore, we performed a knee-puncture and we removed about 120 ml purulent fluid – all routine microbiologic culture tests were negative, however, results of the microbiological culture yielded the presence of acidophilic bacilli. The presence of *Mycobacterium tuberculosis* was confirmed by PCR analysis (MTD Gen-Probe). This specimen was cultured in Bactec 460 Tb which re-

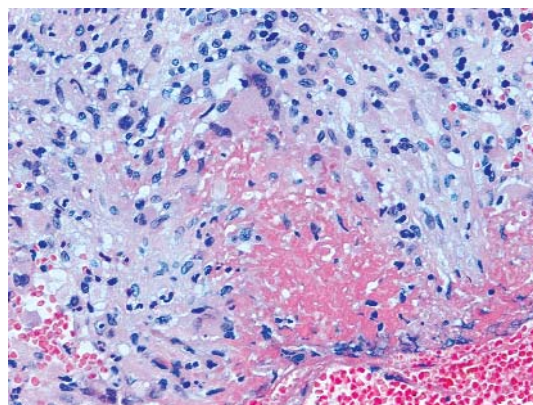
confirmed tuberculosis as well. Due to this diagnosis, we performed skin lesion biopsy and trephine biopsy (because of severe anemia). These two histopathologic examinations revealed features of tuberculosis (Figures 1, 2). PCR analysis of skin biopsy specimen confirmed the presence of *Mycobacterium tuberculosis*. Although, the repeated chest X-ray was normal, a CT scan revealed a picture of hematogenous dissemination of tuberculosis. According to these findings the final diagnosis was miliary tuberculosis, probably due to the delay in diagnosis. The patient started treatment with 4 tuberculostatics – isoniazid, rifampicin, ethambutol and streptomycin [6] and after 2 weeks, because of increasing liver tests, therapy was reduced to streptomycin and ethambutol [6]. His ailments were resolving during this treatment and peripheral blood counts were improving. After six months of treatment the patient remained in a good clinical status, without features of tuberculosis. The last evaluation revealed a person in CR1 of AML and 100% donor chimerism without necessity of any treatment.

## Discussion

Tuberculosis is rare but serious opportunistic infection following allogeneic stem cell transplantation [2, 3, 5]. Mycobacterial infections (MBIs) are localized mainly in lungs, but extrapulmonary presentation is emerging among transplant recipients or HIV infected patients [3, 7-9]. The incidence and mortality due to MBIs among the allogeneic transplant recipients in Europe is rather low (0.42 and 16% respectively) [3], but the problem lies in the long mean delay between first symptoms and the appropriate diagnosis (29 days, range 0-210 days) [3, 9]. It may be longer (median 37 days) in the group of patients on a corticosteroid therapy (due to acute or chronic GvHD) [3]. MBIs are rather not associated with neutropenia but with the loss of T cell surveil-



**Figure 1.** Trephine biopsy showing several granulomas composed of epithelioid and giant cells. Hematoxylin and eosin stain, 100×



**Figure 2.** Epithelioid granuloma with central caseous necrosis and multinucleated giant cells in the skin. Hematoxylin and eosin stain, 100×

lance [3, 5]. In our case two major factors were responsible for this situation – alemtuzumab and 2-CDA used in conditioning regimen and cyclosporine A as a prophylaxis for GvHD. Immunosuppressive therapy is a main cause and can alternate clinical picture of MBIs among stem cell transplant recipients [3, 5, 7, 9]. Immunocompromised patients may be hyporeactive, without fever, with atypical localizations of the disease like skin, bone marrow, central nervous system, urinary tract and the worst – septic shock with multiorgan failure [3, 5, 10, 11]. Each of these atypical features may be observed in more frequent infectious complications after stem cell transplantation (like bacterial, viral or fungal opportunistic infections) and cause a delay in our thinking about the tuberculosis [12, 13].

In conclusion, our report indicates that tuberculosis might be considered a cause of opportunistic infections after allogeneic stem cell transplantation. It is worth remembering this possibility in diagnostic procedures of FUO (fever of unknown origin) or atypical signs and symptoms in this group of patients, especially in extrapulmonary localisations, and apply prompt and appropriate diagnostic tools.

## References

1. Falzon D, Ait-Belghiti F. What is tuberculosis surveillance in the European Union telling us? *Clin Infect Dis* 2007; 44: 1261-7.
2. Campos A, Vaz CP, Campilho F, et al. Central nervous system (CNS) tuberculosis following allogeneic stem cell transplantation. *Bone Marrow Transplant* 2000; 25: 567-9.
3. Cordonnier C, Martino R, Trabasso P. Mycobacterial infection: a difficult and late diagnosis in stem cell transplant recipients. *Clin Infect Dis* 2004; 38: 1229-36.
4. Menzies D, Khan K. Diagnosis of tuberculosis infection and disease. In: Long R, Cook V, editors. 6<sup>th</sup> Edition Canadian Tuberculosis Standards, Public Health Agency of Canada 2007; 53-91.
5. Erdstein AA, Daas P, Bradstok KF, Robinson T, Hertzberg MS. Tuberculosis in stem cell transplant recipients: still a problem in the 21<sup>st</sup> century. *Transplant Infect Dis* 2004; 6: 142-6.
6. Hoepfner VH, Ward H, Elwood K. Treatment of tuberculosis disease and infection. In: Long R, Cook V (eds.). 6<sup>th</sup> Edition Canadian Tuberculosis Standards, Public Health Agency of Canada 2007; 114-45.
7. Higuchi S, Ishihara S, Kobayashi H, Arai T. A mass lesion in the wrist: a rare manifestation of tuberculosis. *Intern Med* 2008; 47: 313-6.
8. Mathew J, Raj M, Dutta TK, Badhe BA, Sahoo R, Venkatesan M. Extra-pulmonary tuberculosis presenting as obstructive jaundice. *Arch Med Sci* 2007; 3: 73-5.
9. Camara R, Martino R, Granados E, et al. Tuberculosis after hematopoietic stem cell transplantation: incidence, clinical characteristics and outcome. *Bone Marrow Transplant* 2000; 26: 291-8.
10. Yang Z, Kong Y, Wilson F, et al. Identification of risk factors for extrapulmonary tuberculosis. *Clin Infect Dis* 2004; 38: 199-205.
11. Kwara A, Roahen-Harrison S, Prystowsky E, et al. Manifestations and outcome of extra-pulmonary tuberculosis: impact of human immunodeficiency virus co-infection. *Int J Tuberc Lung Dis* 2006; 9: 485-93.
12. Miller LG, Asch SM, Yu EI, Knowles L, Gelberg L, Davidson P. A population-based survey of tuberculosis symptoms: how atypical are typical presentations? *Clin Infect Dis* 2000; 30: 293-9.
13. Storla DG, Yimer S, Bjune GA. A systematic review of delay in the diagnosis and treatment of tuberculosis. *BMC Public Health* 2008; 8: 15.